

Robib and Telemedicine

May 2004 Telemedicine Clinic in Robib

Report and photos compiled by Rithy Chau, Telemedicine Physician Assistant at SHCH

On Monday, May 10, 2004, SHCH staff, Nurse Koy Somontha and PA Rithy Chau, traveled to Preah Vihear for the monthly Robib Telemedicine (TM) Clinic.

The following day, Tuesday, May 11, 2004, the Robib TM clinic opened to receive the patients for evaluations. There were 3 new cases and 8 follow-up patients. The patients were examined and their data were transcribed along with digital pictures of the patients, then transmitted and received replies from their TM partners in Boston and Phnom Penh on the next day.

On Thursday, May 13, 2004, replies from both the Sihanouk Hospital Center of HOPE in Phnom Penh and the Partners Telemedicine in Boston were downloaded. Per advice from these two locations, Nurse Koy Somontha managed and treated the patients accordingly. Finally, the data of the patient concerning final diagnosis and treatment/management would then be transcribed and transmitted to the PA Rithy Chau at SHCH who compiled and sent for website publishing.

The followings detail e-mails and replies to the medical inquiries communicated between Robib TM Clinic and their TM partners in Phnom Penh and Boston :

-----Original Message-----

From: TM Team [mailto:tmrural@yahoo.com]

Sent: Tuesday, May 04, 2004 2:14 PM

To: Ruth Tootill; Rithy Chau; Cornelia Haener; Jennifer Hines; Gary Jacques; Joseph Kvedar; Bunse Leang; Jack Middlebrook; SoThero Noun

Cc: Heather Brandling Bennett; Kathy Kelleher-Fiamma; Kiri; Bernie Krisher; Nancy Lugn; Seda

Subject: To inform about Robib TM of May

Dear all,

I am writing to inform you about the next Robib TM visit. We set up the schedule for this month from 10th of May to 14th of May.

Here is the detail agenda for the visit of May 2004:

- 10 May Leave PP for Robib
- 11 May Robib clinic will begin at 8:00 AM
- 12 May Data entering and transmitting
- 13 May Downloading replies
Patient treatment/management
Return to PP

Please be advise that Mr. Rithy Chau will travel with me to help facilitate the changes in the project. I would appreciate your patience with me. Please feel free to make comments on what will or will not work with this new set up for the Robib visit.

Thank you for cooperation and support.

Best Regards,

Montha

-----Original Message-----

From: TM Team [mailto:tmrural@yahoo.com]

Sent: Wednesday, May 12, 2004 4:30 PM

To: Rithy Chau; Jennifer Hines; Bunse Leang; Heather Brandling Bennett; Paul Heinzelmann; Kathy Kelleher-Fiamma; Joseph Kvedar

Cc: Somontha Koy; Bernie Krisher; Nancy Lugn; SoThero Noun

Subject: Robib TM Clinic May 04, Patient 01, Tan Kim Horn, 55F

Dear All,

During our May 04 TM clinic, we have 11 cases to present to you and need reply for each case by 9:00 AM (Cambodian time) at the latest on Thursday, May 13.

Here is the first case and photo.

Regards,

Montha

Please send all replies to tmrural@yahoo.com and cc: to tmed_rithy@online.com.kh and tmed_project@online.com.kh.

The information transmitted in this e-mail is intended only for the person or entity to which it is addressed and may contain confidential and/or privileged material. Any review, retransmission, dissemination or other use of or taking of any action in reliance upon, this information by persons or entities other than the intended recipient is prohibited. If you received this e-mail in error, please contact the sender and delete material from any computer.

**Robib Telemedicine Clinic
Sihanouk Hospital Center of HOPE and Partners in Telemedicine
Rovieng Commune, Preah Vihear Province, Cambodia**



Patient: Tan Kim Horn 55y F Thnout Malou village

CC: weakness, frequency of urination for 3 months

HPI: 55f, presented with weakness, frequency of urination, thirsty, blurred vision, weight loss about 8kgs for 3 months. Last month on 10/04/04, she went to see medical assistant at pravihea provincial hospital for consultation, she has been diagnosed with DMII. She was covered with DM drug such as Metformine 850mg 2 times per day for 13 days, later on, she stop using it anymore because all the symptoms still keep the same.

PMH: unremarkable

SH: no smoking, no drinking alcohol

FH: her mother has HTN

Allergies: PNC

ROS: weight loss 8kg, no fever, no cough, no palpitation, no chest pain, no GI complaint.

PE:

VS: BP 130/80 P 88 R 20 T 36.5 Wt 58kgs

Gen: look stable and good orientation

HEENT: no oropharyngeal lesion, good pink color of conjunctiva .
Neck, no JVD, no goiter seen, no lymphnode palpable

Chest: Lungs clear both sides. Heart RRR, no murmur

Abd: soft, flat, no tender, no HSM, positive bowel sound

MS/Neuro: Limbs: no deformity, no pitting edema. Neuro exam:
unremarkable

Other: none

Previous Labs/Studies:

Lab/Study Requests: UA(glucose +++++), Fasting Blood Sugar =
186mg/dl

Assessment:

1. DMII

Plan:

1. We would like to do some blood work such as Lytes, Creat,
Bun, Cholesterol, Glycemia, CBC done at SHCH.
2. Give DMII education
3. Will be started treatment next visit

Comments: please, give me good idea.

Examined by: Koy Somontha, RN **Date:** 12/05/04

Please send all replies to tmrural@yahoo.com and cc: to tmed_rithy@online.com.kh and tmed_project@online.com.kh. If unable to send to the first address, please send replies to tmed_ruralcam@yahoo.com as an alternative address.

The information transmitted in this e-mail is intended only for the person or entity to which it is addressed and may contain confidential and/or privileged material. Any review, retransmission, dissemination or other use of or taking of any action in reliance upon, this information by persons or entities other than the intended recipient is prohibited. If you received this e-mail in error, please contact the sender and delete material from any computer.

-----Original Message-----

From: Kelleher-Fiamma, Kathleen M. - Telemedicine

Sent: Wednesday, May 12, 2004 7:44 AM

To: Cusick, Paul S.,M.D.

Subject: FW: Robib TM Clinic May 04, Patient 01, Tan Kim Horn, 55F

Thank you Dr. Cusick.

-----Original Message-----

From: Cusick, Paul S.,M.D. [mailto:PCUSICK@PARTNERS.ORG]
Sent: Thursday, May 13, 2004 12:12 AM
To: Kelleher-Fiamma, Kathleen M. - Telemedicine
Cc: 'tmrural@yahoo.com'; 'tmed_rithy@online.com.kh'; 'tmed_project@online.com.kh'
Subject: RE: Robib TM Clinic May 04, Patient 01, Tan Kim Horn, 55F

She has clinical and laboratory evidence of DM2. She should be instructed in a low carbohydrate diet and started on metformin or oral antihypoglycemic agent. I would check fasting labs as you are doing.

She may need a month or more of therapy w/ hypoglycemic agent before her symptoms improve.

Best of luck

Paul Cusick MD

-----Original Message-----

From: Bunse LEANG [mailto:tmed1shch@online.com.kh]
Sent: Thursday, May 13, 2004 8:07 AM
To: 'TM Team'
Cc: 'Somontha Koy'; 'Bernie Krisher'; 'SoThero Noun'; 'Rithy Chau'; 'Jennifer Hines'; Gary Jacques
Subject: RE: Robib TM Clinic May 04, Patient 01, Tan Kim Horn, 55F

Dear Montha,

I will answer the first 6 cases and Jennifer will do the rest.

Her symptoms of polyuria, polydipsia, weight loss, blurred vision are compatible with diabetes mellitus and also told so by her doctor. She is obese by the attached picture.

Despite metformin her symptoms were not better. I wonder whether she was not better or did she experienced any symptoms of hypoglycemia during metformin: fatigue, weakness, palpitation, sweating, moist cold skin, feeling hungry...?

It sounds like she stopped metformin several days ago and her fasting BS 186 mg/dL, though UA shown glucose 4+. Therefore, I would agree with your plans of diabetes education, diet, exercises, weight reduction... and check the above mentioning labs. Please add ECG, CXR, transaminase and urine microscopy also.

I think those tests can be done at Kg. Thom, and if she can afford, that would be great and there is no need to come to SHCH.

Regards,

Bunse

-----Original Message-----

From: TM Team [mailto:tmrural@yahoo.com]
Sent: Wednesday, May 12, 2004 4:38 PM
To: Rithy Chau; Jennifer Hines; Bunse Leang; Heather Brandling Bennett; Paul Heinzelmann; Kathy Kelleher-Fiamma; Joseph Kvedar
Cc: Somontha Koy; Bernie Krisher; Nancy Lugn; SoThero Noun
Subject: Robib TM Clinic May 04, Patient 02, Phnom Sokchea, 9M

Dear All,

Here is the second case and photo.

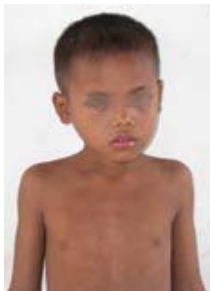Regards,

Montha

Please send all replies to tmrural@yahoo.com and cc: to tmed_rithy@online.com.kh and tmed_project@online.com.kh.

The information transmitted in this e-mail is intended only for the person or entity to which it is addressed and may contain confidential and/or privileged material. Any review, retransmission, dissemination or other use of or taking of any action in reliance upon, this information by persons or entities other than the intended recipient is prohibited. If you received this e-mail in error, please contact the sender and delete material from any computer.

**Robib Telemedicine Clinic
Sihanouk Hospital Center of HOPE and Partners in Telemedicine
Rovieng Commune, Preah Vihear Province, Cambodia**



Patient: Phnom Sok Chea, 9M, Thnal Keng village

CC: Productive cough and fever for 7 days

HPI: 9 years old male, student, presented with slight green sputum, fever, sob, for 7 days. His mother has given him Paracetamol 500mg PO 2 times per day o and off for 5 days. But all the symptoms are not released. Last night he has also complained of localized abdominal pain at left side, but no diarrhea or stool with blood. He already completed vaccinations.

PMH: Unremarkable

SH: unremarkable

FH: unremarkable

Allergies: NKA

ROS: no sore throat, no fever, positive productive cough, no headache, no palpitation, no diarrhea

PE:

VS: BP 90/40 P 84 R 28 T 37.5 Wt 19kgs

Gen: not distress

HEENT: n oropharyngeal lesion, mild pink of conjunctiva. Skin is warm to touch. Neck no lymphnode palpable.

Chest: Lungs: Crackle all over lobes. Heart: RRR, no murmur

Abd: soft, flat, no tender, no mas palpable, positive bowel sound

MS/Neuro: limbs no edema, no deformity

Other: none

Previous Labs/Studies: none

Lab/Study Requests:

Assessment:

2. Pneumonia
3. Parasites
4. Malnutrition

Plan:

4. Amoxicilline 250mg 1tab PO 3 times per day for 7 days
5. Paracetamol 500mg ½ tab PO 4 times per day for PRN
6. Mebendazole 100mg 1 tab PO 2 times per day for 3 days
7. Multivitamine 1tab PO 1 time per day for 1 month

Comments: If you have any idea, please give me

-----Original Message-----

From: Kelleher-Fiamma, Kathleen M. - Telemedicine
[mailto:KKELLEHERFIAMMA@PARTNERS.ORG]
Sent: Thursday, May 13, 2004 2:15 AM
To: 'tmrural@yahoo.com'
Cc: 'tmed_rithy@online.com.kh'; 'tmed_project@online.com.kh'
Subject: RE: Robib TM Clinic May 04, Patient 02, Phnom Sokchea, 9M

This case, with the more acute onset, sounds like pneumonia.

I would however consider a PPD.

Amox is a good first choice.

Sincerely,

Kenan Haver, M.D.

-----Original Message-----

From: Bunse LEANG [mailto:tmed1shch@online.com.kh]
Sent: Thursday, May 13, 2004 8:39 AM
To: 'TM Team'
Cc: 'Somontha Koy'; 'Bernie Krisher'; 'SoThero Noun'; 'Rithy Chau'; 'Jennifer Hines'; Gary Jacques
Subject: RE: Robib TM Clinic May 04, Patient 02, Phnom Sokchea, 9M

Dear Montha,

The boy's noses look like he is having runny nose, doesn't he? If he is having runny nose, and he is not in distress with this temperature of 37.5C, crackle both lungs I would think more of viral URTI if there is no underlying heart diseases. Please ask his mother if the boy had history of SOB on exertion, or cyanosis, ever told by his doctor that he has heart diseases. Also be aware of asthma, please ask history of asthma.

The fact that the boy has abdominal pain (is it upper quadrant?) would make me agree with your amoxicillin. Just make sure the boy does not cough like a whooping cough (though he completed vaccination series he still could have Pertussis), and antibiotic would be erythromycin to shorten infectiousness, but not to shorten his cough.

Cough from URTI may persist up to 3 weeks, please let the mother know.

In summary, agree with your plan, however if the boy is getting worse the mother should bring him to the hospital.

Regards,

Bunse

-----Original Message-----

From: TM Team [mailto:tmrural@yahoo.com]

Sent: Wednesday, May 12, 2004 4:46 PM

To: Rithy Chau; Jennifer Hines; Bunse Leang; Heather Brandling Bennett; Paul Heinzelmann; Kathy Kelleher-Fiamma; Joseph Kvedar

Cc: Somontha Koy; Bernie Krisher; Nancy Lugn; SoThero Noun

Subject: Robib TM Clinic May 04, Patient 03, Cheng Rady, 9F

Dear All,

Here is the third case and photo.

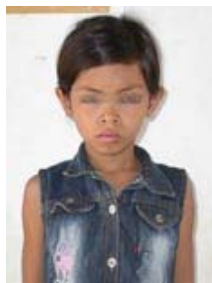Regards,

Montha

Please send all replies to tmrural@yahoo.com and cc: to tmed_rithy@online.com.kh and tmed_project@online.com.kh.

The information transmitted in this e-mail is intended only for the person or entity to which it is addressed and may contain confidential and/or privileged material. Any review, retransmission, dissemination or other use of or taking of any action in reliance upon, this information by persons or entities other than the intended recipient is prohibited. If you received this e-mail in error, please contact the sender and delete material from any computer.

Robib Telemedicine Clinic
Sihanouk Hospital Center of HOPE and Partners in Telemedicine
Rovieng Commune, Preah Vihear Province, Cambodia



Patient: Cheng Rady, 9F Thnout Malou village

CC: Productive cough and fever for one month

HPI: 9F, presented with productive cough, fever on and off for one month. Last 20 days ago, she had high fever, her mother took her to local pharmacy, they gave her some pills of Amoxicillin and Paracetamol, she just took those on and off while only she has severe cough and fever. All the symptoms still have such cough, mild fever, weakness.

PMH: Last year she had severe Pharyngitis.

SH: unremarkable

FH: unremarkable

Allergies: NKA

ROS: weight loss 2 kgs during 3 months, mild fever, productive cough, headache, no sore throat, no diarrhea, no abdominal pain.

PE:

VS: BP 90/40 P 88 R 20 T 37.5 Wt 18kgs

Gen: look non toxic

HEENT: no oropharyngeal lesion, no ear discharging, good pink conjunctiva. Neck no lymphnode palpable

Chest: Lungs: crackle at Lower bilateral lobes. Heart: RRR, no murmur

Abd: soft, flat, no tender, no HSM, positive bowel sound

MS/Neuro: Limbs: no pitting edema, no joint pain

Other: none

Previous Labs/Studies none

Lab/Study Requests: none

Assessment:

5. Pneumonia
6. Parasites

Plan:

8. Erythromycine 250mg 1tab PO 4 time per day for 7 days
9. Mebendazole 100mg 1 tab PO 2 times per day for 3 days
10. Paracetamol 500mg ½ tab PO 4 times per day PRN

Comments: If yo have an comment or idea, please give me

-----Original Message-----

From: Kelleher-Fiamma, Kathleen M. - Telemedicine

[mailto:KKELLEHERFIAMMA@PARTNERS.ORG]

Sent: Friday, May 14, 2004 6:25 PM

To: 'tmed_rithy@online.com.kh'

Cc: Lugn, Nancy E.

Subject: FW: Robib TM Clinic May 04, Patient 03, Cheng Rady, 9F

Hello Rithy:

I understand that you did not receive this response, so I am re-sending.

Best regards,

Kathy

-----Original Message-----

From: Kelleher-Fiamma, Kathleen M. - Telemedicine
Sent: Wednesday, May 12, 2004 3:17 PM
To: 'tmrural@yahoo.com'
Cc: 'tmed_rithy@online.com.kh'; 'tmed_project@online.com.kh'
Subject: RE: Robib TM Clinic May 04, Patient 03, Cheng Rady, 9F

For the second patient, going one for months with weight, makes TB more of a concern.

I would also be concerned about her immune status and consider HIV.

Not clear why a macrolide was chosen as first line therapy but not unreasonable.

Kenan Haver, M.D.

-----Original Message-----

From: Bunse LEANG [mailto:tmed1shch@online.com.kh]
Sent: Thursday, May 13, 2004 9:06 AM
To: 'TM Team'
Cc: 'Somontha Koy'; 'Bernie Krisher'; 'SoThero Noun'; 'Rithy Chau'; 'Jennifer Hines'; Gary Jacques
Subject: RE: Robib TM Clinic May 04, Patient 03, Cheng Rady, 9F

Dear Montha,

Chronic cough for 1 month with weight loss, T = 37.5C, crackle bilateral lower lobes, had tried amoxicilline and still coughing.

The first I would do is to rule out pulmonary TB. Please check sputum AFB, and if negative do a CXR. At the meantime, like CENAT guideline says, give antibiotics. I would agree with your erythromycin as the girl already tried amoxicillin, and by this time community acquired pneumonia would be unlikely. Review again after AFB and CXR. May be you ask help from Kg. Thom hospital, TB unit.

Then ask if she has post nasal drip, itchy nose, throat or eyes for allergic rhinitis also cause chronic cough. Whooping cough could last 6 weeks, look and listen to the pattern she is coughing.

Rule out asthma by asking history: cough often at night and early morning with SOB and wheeze, seasonal, URTI induced, family history of asthma, presence of eczema. Rule out cardiac causes, any SOB on exertion, orthopnea, cyanosis, history of heart diseases told by her doctor...

In summary, agree with your plans, rule out above things.

Regards,

Bunse

-----Original Message-----

From: TM Team [mailto:tmrural@yahoo.com]
Sent: Wednesday, May 12, 2004 4:52 PM
To: Rithy Chau; Jennifer Hines; Bunse Leang; Heather Brandling Bennett; Paul

Heinzelmann; Kathy Kelleher-Fiamma; Joseph Kvedar
Cc: Somontha Koy; Bernie Krisher; Nancy Lugn; SoThero Noun
Subject: Robib TM Clinic May 04, Patient 04, Lay Neung, 35F

Dear All,

Here is the fourth case and photos.

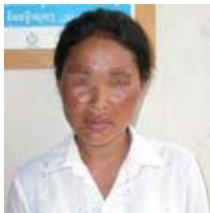Regards,

Montha

Please send all replies to tmrural@yahoo.com and cc: to tmed_rithy@online.com.kh and tmed_project@online.com.kh.

The information transmitted in this e-mail is intended only for the person or entity to which it is addressed and may contain confidential and/or privileged material. Any review, retransmission, dissemination or other use of or taking of any action in reliance upon, this information by persons or entities other than the intended recipient is prohibited. If you received this e-mail in error, please contact the sender and delete material from any computer.

**Robib Telemedicine Clinic
Sihanouk Hospital Center of HOPE and Partners in Telemedicine
Rovieng Commune, Preah Vihear Province, Cambodia**



Patient: Lay Neung, 35F, Sleing Toul

Subject: follow up patient from last month, she still has palpitation, positive slight headache, neck tender, dizziness, epigastric pain with excessive saliva. Last we also sent her to KG Thom to do EKG and CXR (support by her own) as you see in the attached pictures. Furthermore, we also do some blood work at SHCH and show result in previous studies

Object:

VS: BP 110/70 P 70 R 20 T 36.5 Wt 46kgs

HEENT : Unremarkable

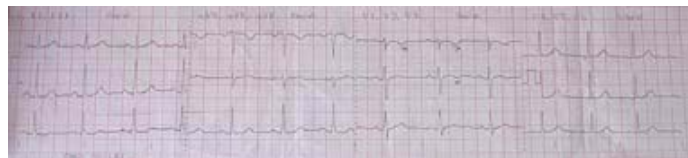Neck : no JVD, no Thyroide glance seen

Lungs: clear both sides

Heart: RRR, no murmur

Abdomen: soft, flat, no tender, positive bowel sound, no pain palpable

Libms: no tremor, no edema



Previous Labs/Studies: lab test done on 08/04/04 at SHCH

Na+: 136mmol/L

K+: 5.7mmol/L(elevate possible due to hemolysis blood)

Creat: 63 umol/L

BS: 5 mmol/L

TSH: 0.06 micro IU/ml

T4: 14 pml/L

Lab/Study Requests: none

Assessment:

7. Euthyroid?
8. Dyspepsia?
9. Parasites?
10. Tension headach

Plan:

11. Tump 1g 1tab PO 2 times per day for 2 months
12. Paracetamol 500mg 1 tab PO 4 times per day for PRN
13. Mebendazole 100mg 1 tab PO 2 times per day for 3 days
14. Follow up her next two months for Euthyroid observation

Comments: if you have any idea or comment please give me

Examined by: Koy Somontha, RN **Date:** 12/05/04

Please send all replies to tmrural@yahoo.com and cc: to tmed_rithy@online.com.kh and tmed_project@online.com.kh. If unable to send to the first address, please send replies to tmed_ruralcam@yahoo.com as an alternative address.

The information transmitted in this e-mail is intended only for the person or entity to which it is addressed and may contain confidential and/or privileged material. Any review, retransmission, dissemination or other use of or taking of any action in reliance upon, this information by persons or entities other than the intended recipient is prohibited. If you received this e-mail in error, please contact the sender and delete material from any computer.

-----Original Message-----

From: Kelleher-Fiamma, Kathleen M. - Telemedicine
[mailto:KKELLEHERFIAMMA@PARTNERS.ORG]

Sent: Thursday, May 13, 2004 7:56 AM

To: 'tmrural@yahoo.com'

Cc: 'tmed_rithy@online.com.kh'; 'tmed_rithy@bigpond.com.kh';
'tmed_project@online.com.kh'

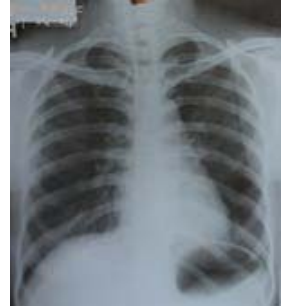Subject: RE: Robib TM Clinic May 04, Patient 04, Lay Neung, 35F

-----Original Message-----

From: Guiney, Timothy E.,M.D.

To: Kelleher-Fiamma, Kathleen M. - Telemedicine

Sent: 5/12/04 6:46 PM



Subject: RE: Robib TM Clinic May 04, Patient 04, Lay Neung, 35F

The laboratory data suggests that she may be borderline hyperthyroid. Suggest repeating the studies as you plan to do. Would also be very sure that none of her herbal medications contains any

thyroid-active components.

The ECG and CXR are both normal.

Timothy Guiney, M.D.

-----Original Message-----

From: Bunse LEANG [mailto:tmed1shch@online.com.kh]

Sent: Thursday, May 13, 2004 10:07 AM

To: 'TM Team'

Cc: 'Somontha Koy'; 'Bernie Krisher'; 'SoThero Noun'; 'Rithy Chau'; 'Jennifer Hines'; Gary Jacques

Subject: RE: Robib TM Clinic May 04, Patient 04, Lay Neung, 35F

Dear Montha,

Her TSH = 0.06 umol/mL (0.47-0.51) is low but T4 is normal, so she is having subclinical hyperthyroid by definition.

She has palpitation, but ECG looks normal and regular HR of 70-75/min. She is young, no goiter, no radioiodine uptake test, no bone scan test, I would thus agree to observe and follow her TSH.

Neck tender and headache:

1. It is possible that she has tension headache, frequently associated with anxiety disorder. She also has excessive salivation. Amitriptyline 25 mg, started 1/4 q HS for 1 week, increase to 1/2 for 1 week, then increase to 1 would help also tension headache and excessive saliva (you should rule out pregnancy hyperemesis!) and help her sleep which could be caused by her subclinical hyperthyroid. Propranolol low dose 10 mg BID would also help tension headache, her palpitation by anxiety and hyperthyroidism. Reassurance and counseling are of great value.

2. If possible please do cervical spine X-ray to rule out spine problems that cause neck tender and headache.

Agree with your Tums, mebendazole and paracetamol.

Regards,

Bunse

-----Original Message-----

From: TM Team [mailto:tmrural@yahoo.com]

Sent: Wednesday, May 12, 2004 5:00 PM

To: Rithy Chau; Jennifer Hines; Bunse Leang; Heather Brandling Bennett; Paul Heinzelmann; Kathy Kelleher-Fiamma; Joseph Kvedar

Cc: Somontha Koy; Bernie Krisher; Nancy Lugn; SoThero Noun

Subject: Robib TM Clinic May 04, Patient 05, Thorng Khun, 39F

Dear All,

Here is the fifth case and photo.

Regards,

Montha

Please send all replies to tmrural@yahoo.com and cc: to tmed_rithy@online.com.kh and tmed_project@online.com.kh.

The information transmitted in this e-mail is intended only for the person or entity to which it is addressed and may contain confidential and/or privileged material. Any review, retransmission, dissemination or other use of or taking of any action in reliance upon, this information by persons or entities other than the intended recipient is prohibited. If you received this e-mail in error, please contact the sender and delete material from any computer.

Robib Telemedicine Clinic
Sihanouk Hospital Center of HOPE and Partners in Telemedicine
Rovieng Commune, Preah Vihear Province, Cambodia



Patient: Thorng Khun, 39F Thnout Malou

Subject: 39F, come for her follow up of Euthyroidism. She still has neck tender, chest tightness sometimes, head ache, mild palpitation. But n fever, no SOB, no Gi complain

Object:

VS: BP 100/60 P90 R 20 T 36.5 Wt 57kgs

HEENT : unremarkable

Neack : goiter glance is the same size, not growing up (around neck is 32cm)

Lungs: clear both sides

Heart: RRR, no murmur

Abd: soft, flat, no tener, positive bowel sound, no HSM

Previous Labs/Studies: please, look at in her previous report

Lab/Study Requests: none

Assessment:

11. Euthyroide with breast feeding 5 months child
12. Tension head ache

Plan:

15. Multivitamine 1tab PO 1 time per day for 2 months

16. Paracetamol 500mg 1tab PO 4 times per day for PRN
17. Suggest to stop Fer Follic acid because she has been covered 7 months already

Comments: if you have any comment or good idea please give me

Examined by: Koy Somontha, RN **Date:** 12/05/04

Please send all replies to tmrural@yahoo.com and cc: to tmed_rithy@online.com.kh and tmed_project@online.com.kh. If unable to send to the first address, please send replies to tmed_ruralcam@yahoo.com as an alternative address.

The information transmitted in this e-mail is intended only for the person or entity to which it is addressed and may contain confidential and/or privileged material. Any review, retransmission, dissemination or other use of or taking of any action in reliance upon, this information by persons or entities other than the intended recipient is prohibited. If you received this e-mail in error, please contact the sender and delete material from any computer.

-----Original Message-----

From: Paul [mailto:ph2065@yahoo.com]

Sent: Thursday, May 13, 2004 5:31 AM

To: tmrural@yahoo.com; tmed_rithy@online.com.kh; tmed_project@online.com.kh

Cc: kkelleher-fiamma@partners.org; kkelleherfiamma@partners.org

Subject: Patient #6: THORN KHUN, female, 38 years old, follow up patient

Patient #6: THORN KHUN, female, 38 years old, follow up patient

Thank you for the follow-up. You report that she is euthyroid. I couldn't find the last TSH or T4 for her, but I assume that they are now normal. If her tests show that she is euthyroid there is obviously no need to treat her. (I believe some kind of record-keeping of lab values would make the telemedicine clinic more valuable for the RN and PA there and for our doctors. Perhaps we should think of ways to make that happen. What do you think?). It seems her headaches have been present for months now. More details about the headaches would be helpful. (location, duration, triggers, visual changes, quality) Her heart rate isn't tachycardic but it is in the high range. Mild dehydration should be ruled out as it can both cause a headache and raise the heart rate. Orthostatic blood pressures could be done: have her lie down for 2 minutes, then take her heart rate and blood pressure. Then have her stand for 2 minutes and repeat the heart rate and blood pressure. A 20 point drop in systolic BP or a 20 point rise in heart rate with the standing vital signs is a better indication of dehydration. Dizziness upon standing is also suggestive. As in my previous recommendation, she needs evaluation with an ophthalmoscope if she is experiencing blurred vision.

If it appears she is dehydrated, I would recommend she drink more water, and decrease her intake of any caffeine-containing drinks. Because of her apparent goiter, a TSH/T4 in the future may need to be repeated.

Yes, there is no need for the folic acid. If available, multivitamins are helpful as long as she is breast feeding.

Thank you,

Paul Heinzlmann, MD

-----Original Message-----

From: Bunse LEANG [mailto:tmed1shch@online.com.kh]

Sent: Thursday, May 13, 2004 10:12 AM

To: 'TM Team'

Cc: 'Somontha Koy'; 'Bernie Krisher'; 'SoThero Noun'; 'Rithy Chau'; 'Jennifer Hines'; Gary Jacques
Subject: RE: Robib TM Clinic May 04, Patient 05, Thorng Khun,39F

Dear Montha,

Agree with your plans. Follow her and keep eyes on her symptoms and thyroid functions.

Regards,

Bunse

-----Original Message-----

From: TM Team [mailto:tmrural@yahoo.com]

Sent: Wednesday, May 12, 2004 5:19 PM

To: Rithy Chau; Jennifer Hines; Bunse Leang; Heather Brandling Bennett; Paul Heinzelmann; Kathy Kelleher-Fiamma; Joseph Kvedar

Cc: Somontha Koy; Bernie Krisher; Nancy Lugn; SoThero Noun

Subject: Robib TM Clinic May 04, Patient 06, Som Doeum

Dear all,

This is the sixth case and photos,

Regards,

Montha

Please send all replies to tmrural@yahoo.com and cc: to tmed_rithy@online.com.kh and tmed_project@online.com.kh.

The information transmitted in this e-mail is intended only for the person or entity to which it is addressed and may contain confidential and/or privileged material. Any review, retransmission, dissemination or other use of or taking of any action in reliance upon, this information by persons or entities other than the intended recipient is prohibited. If you received this e-mail in error, please contact the sender and delete material from any computer.

Robib Telemedicine Clinic
Sihanouk Hospital Center of HOPE and Partners in Telemedicine
Rovieng Commune, Preah Vihear Province, Cambodia



Patient: Som Deum, 65F, Thnout Malou

Subject: 65F, returned for her follow up visit of her Polyarthritis. She still has both knees and all finger joint pain, poor appetite, but no fever, no cough, no SOB, no chest pain, no GI complain. Last month we sent her to Kg Thom Hospital for hands X RAY(patient support by her own), please help us to make a conclusion with that X Ray thought our attached pictures

Object:

VS: BP 100/50 P 80 R 20 T 36 Wt 36

HEENT : no oropharyngeal lesion, no pale

Neck: no JVD, no thyroide glance seen

Lungs: clear both sides

Heart: RRR, no murmur

Abd: soft, flat, ntender, no HSM, positive bowel sound

Lims: still pain for all finger joints, knee joints, but no swelling

Previous Labs/Studies: Hands X Ray done last two weeks ago

Lab/Study Requests: none

Assessment:

13. Poly arthritis

Plan: we would cover her same medications for 2 months and follow up her next two months

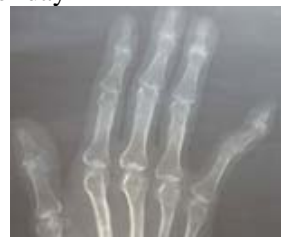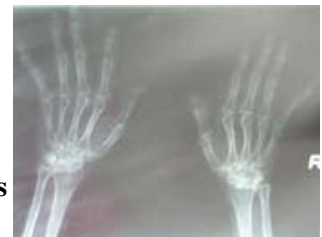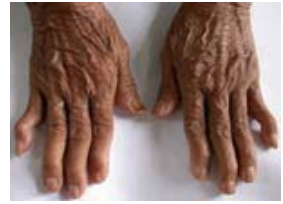18. Nabumetone 75mg 1tab PO 2 times per day

19. Chlroquine 250mg 1tab PO 1 time per day

Comments: if you have any idea or coment, please give me

Examined by: Koy Somontha, RN

Date: 12/05/04



Please send all replies to tmrural@yahoo.com and cc: to tmed_rithy@online.com.kh and tmed_project@online.com.kh. If unable to send to the first address, please send replies to tmed_ruralcam@yahoo.com as an alternative address.

The information transmitted in this e-mail is intended only for the person or entity to which it is addressed and may contain confidential and/or privileged material. Any review, retransmission, dissemination or other use of or taking of any action in reliance upon, this information by persons or entities other than the intended recipient is prohibited. If you received this e-mail in error, please contact the sender and delete material from any computer.

-----Original Message-----

From: Paul [mailto:ph2065@yahoo.com]

Sent: Thursday, May 13, 2004 6:26 AM

To: tmrural@yahoo.com; tmed_rithy@online.com.kh; tmed_project@online.com.kh

Cc: kkelleherfiamma@partners.org; kkelleher-fiamma@partners.org

Subject: Patient: Som Deum, 65F, Thnout Malou

Patient: Som Deum, 65F, Thnout Malou

Greetings,

Unfortunately Dr Crocker was unavailable today for follow-up, but I have reviewed her case.

I have looked at her x-ray and although the quality is somewhat poor, it is consistent with rheumatoid arthritis in my opinion. But, as Dr Crocker recommended, a baseline CBC, ESR, Rheumatoid factor, and albumen, AST/ALT would be helpful in her care, because the treatment for rheumatoid arthritis can also be dangerous to other parts of her body such as her liver.

Hydroxychloroquine sulfate (known as Plaquenil in the US) could be helpful. This is NOT the same as chloroquine. Because these medicines are powerful they can damage the liver, and that is why the ALT/AST lab tests are important if a patient starts this medicine.

If you can get hydroxychloroquine sulfate, you should start at: 400 mg/day to start taken with food or milk; and increase until optimum response level is reached; After 2-3 months you should reduce it to 200-400 mg

She should avoid overuse of her joints, but continue moving them.

I hope this was helpful.

Paul Heinzlmann, MD

-----Original Message-----

From: Bunse LEANG [mailto:tmed1shch@online.com.kh]

Sent: Thursday, May 13, 2004 10:21 AM

To: 'TM Team'

Cc: 'Somontha Koy'; 'Bernie Krisher'; 'SoThero Noun'; 'Rithy Chau'; 'Jennifer Hines'; Gary Jacques

Subject: RE: Robib TM Clinic May 04, Patient 06, Som Doeum

Dear Montha,

There are juxta-articular osteoporosis and joint spaces narrowing, with swan neck deformities, I would say she has RA.

Agree with your plans. Keep taking nabumetone with meals.

Thanks for the cases,

Bunse

-----Original Message-----

From: Jennifer Hines [mailto:jghines@hotmail.com]

Sent: Thursday, May 13, 2004 9:47 AM

To: tmrural@yahoo.com; tmed_rithy@online.com.kh;

tmed_project@online.com.kh

Subject: Telemedicine replies for cases #6-11 Robib Clinic, 13 May 2004

Dear Montha:

I had trouble sending my replies to you via Online, so I am sending them through my hotmail address.

Case #6 Som Doeum

This particular patient appears to have the classic signs of osteoarthritis---the deformities at the end of her fingers or Boutonniere's deformities. This is longstanding and is not reversible. I agree with giving her the Nabumetone, but I am not certain that Chloroquine will help this woman at this point. She has degenerative changes in the hands and not active inflammation. I would consider exercise, like squeezing rolled up cloth or a ball, to help the stiffness in the hands.

You should consider protecting the stomach from the NSAIDS, so if she has not had H. pylori eradication, she should get that. I don't know if you have that regimen in your supplies, so you could give Ranitidine 75mg BID for now and reassess at the next visit.

Thanks, Jennifer

-----Original Message-----

From: TM Team [mailto:tmrural@yahoo.com]

Sent: Wednesday, May 12, 2004 5:38 PM

To: Rithy Chau; Jennifer Hines; Bunse Leang; Heather Brandling Bennett; Paul Heinzelmann; Kathy Kelleher-Fiamma; Joseph Kvedar

Cc: Somontha Koy; Bernie Krisher; Nancy Lugn; SoThero Noun

Subject: Robib TM Clinic May 04, Patient 07, Chan Sokny, 25F

Dear all,

This is the seventh case and photo.

Regards,

Montha

Please send all replies to tmrural@yahoo.com and cc: to tmed_rithy@online.com.kh and tmed_project@online.com.kh.

The information transmitted in this e-mail is intended only for the person or entity to which it is addressed and may contain confidential and/or privileged material. Any review, retransmission, dissemination or other use of or taking of any action in reliance upon, this information by persons or entities other than the intended recipient is prohibited. If you received this e-mail in error, please contact the sender and delete material from any computer.

**Robib Telemedicine Clinic
Sihanouk Hospital Center of HOPE and Partners in Telemedicine
Rovieng Commune, Preah Vihear Province, Cambodia**



Patient: Chan Sokny, 25F

Subject: Patient returns for her follow up of Euthyroide. She feels much better by decreasing SOB, decreasing palpitation, still mild blurred vision, head ached, a little bit eye fatigue, no fever, no chest pain, no cough, no GI complaint.

Object:

VS: BP 120/80 P84 R 20 T 36.5 Wt 55kgs

HEENT : unremarkable

Neck : unremarkable

Lungs : clear both sides

Heart: RRR, no murmur

Abd: soft, flat, no tender, no SHM, positive bowel sound 1

Previous Labs/Studies: please look at in her previous report

Lab/Study Requests: none

Assessment:

14. Euthyroid
15. Tension head ache

Plan: we would cover her with the same of medications for another month

20. Propranolol 40mg 1/4tab PO BID
21. Paracetamol 500mg 1 tab PO 4 times per day for PRN
22. Suggest to recheck her Thyroid test and some blood work like CBC, Creat, BUN which will be done at SHCH.

Comments: if you have any idea or comment, please give me

Examined by: Koy Somontha, RN **Date:** 12/05/04

Please send all replies to tmrural@yahoo.com and cc: to tmed_rithy@online.com.kh and tmed_project@online.com.kh. If unable to send to the first address, please send replies to tmed_ruralcam@yahoo.com as an alternative address.

The information transmitted in this e-mail is intended only for the person or entity to which it is addressed and may contain confidential and/or privileged material. Any review, retransmission, dissemination or other use of or taking of any action in reliance upon, this information by persons or entities other than the intended recipient is prohibited. If you received this e-mail in error, please contact the sender and delete material from any computer.

-----Original Message-----

From: Kelleher-Fiamma, Kathleen M. - Telemedicine

Sent: Wednesday, May 12, 2004 8:21 AM

To: List, James Frank, M.D., Ph.D.

Subject: FW: Robib TM Clinic May 04, Patient 07, Chan Sokny, 25F

Good Morning Dr. List:

Here is a follow up consultation from April.

Please let me know if you are available and please let me know if you need the previously presented material and your response.

Kathy

-----Original Message-----

From: List, James Frank, M.D., Ph.D. [mailto:JLIST@PARTNERS.ORG]

Sent: Thursday, May 13, 2004 12:24 AM
To: Kelleher-Fiamma, Kathleen M. - Telemedicine; 'tmrural@yahoo.com'
Cc: 'tmed_rithy@online.com.kh'; 'tmed_project@online.com.kh';
'tmed_ruralcam@yahoo.com'
Subject: RE: Robib TM Clinic May 04, Patient 07, Chan Sokny, 25F

In summary, the patient is symptomatically improving and has a normal examination. She has a history of subclinical hypothyroidism. She is on propranolol BID and paracetamol PRN.

I agree with the plan outlined. The thyroid function tests should be rechecked. If the TSH is normal, the propranolol should be tapered and then discontinued. Because post-partum depression could be at the root of the patient's complaints, and because propranolol can make depression worse, it should be discontinued if not clearly needed.

If the thyroid function tests are more abnormal (as outlined in the prior responses), appropriate action should be taken. If they are roughly the same as last time, she could be continued on the propranolol.

Again, it would be a good idea to screen for other systemic disease that could cause the patient's symptoms. A CBC, BUN, creatinine, and glucose would be a good start.

James F. List, M.D., Ph.D.

Endocrinology

Massachusetts General Hospital

-----Original Message-----

From: Jennifer Hines [mailto:jghines@hotmail.com]

Sent: Thursday, May 13, 2004 9:47 AM

To: tmrural@yahoo.com; tmed_rithy@online.com.kh;

tmed_project@online.com.kh

Subject: Telemedicine replies for cases #6-11 Robib Clinic, 13 May 2004

Dear Montha:

Case #7 Chan Sokny, 25F

In your examination of these patients with thyroid disease, please document a brief neuro exam and of course, a neck exam. I have no problems with you continuing the current medicines you have her on while you recheck her bloodwork. In your note, it is also helpful to document when her last tests were done and what were their results. We may not have the ability to go back and look up these values from here.

I agree to repeat a TSH and CBC, but I do not know if you need other tests on her.

Thanks, Jennifer

-----Original Message-----

From: TM Team [mailto:tmrural@yahoo.com]

Sent: Wednesday, May 12, 2004 5:57 PM

To: Rithy Chau; Jennifer Hines; Bunse Leang; Heather Brandling Bennett; Paul Heinzelmann; Kathy Kelleher-Fiamma; Joseph Kvedar

Cc: Somontha Koy; Bernie Krisher; Nancy Lugn; SoThero Noun

Subject: Robib TM Clinic May 04, Patient 08, Em Kheav, 43F

Dear all,

This is the eighth case and photos.

Regards,

Montha

Please send all replies to tmrural@yahoo.com and cc: to tmed_rithy@online.com.kh and tmed_project@online.com.kh.

The information transmitted in this e-mail is intended only for the person or entity to which it is addressed and may contain confidential and/or privileged material. Any review, retransmission, dissemination or other use of or taking of any action in reliance upon, this information by persons or entities other than the intended recipient is prohibited. If you received this e-mail in error, please contact the sender and delete material from any computer.

**Robib Telemedicine Clinic
Sihanouk Hospital Center of HOPE and Partners in Telemedicine
Rovieng Commune, Preah Vihear Province, Cambodia**



Patient: Em Kheav, 43F from Thnal Keng village

Subject: 43F, she returns for her follow up of her Thyroid problem. Last trip we drew her blood for doing Thyroid test and some blood work done at SHCH and CXR, EKG at kg Thom support by her own, we will show the result in previous studies culum.

Now she still has head ache, blurred vision, weakness, palpitation, epigastric pain, excessive saliva. But no fever, no cough, no chest pain, no stool with blood.

Object:

VS: BP 110/50 P 90 R 20 T 36.5 Wt 39kg

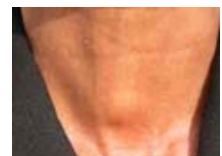HEENT : unremarkable

Neck : one anterior mass, size 3x3cm, smooth surface, positive mobile

Lungs: clear both sides

Heart: RRR, no murmur

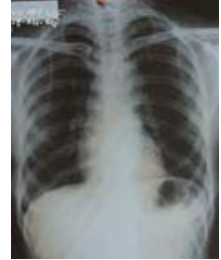Abd: soft, flat, no tender, no HSM, positive BS



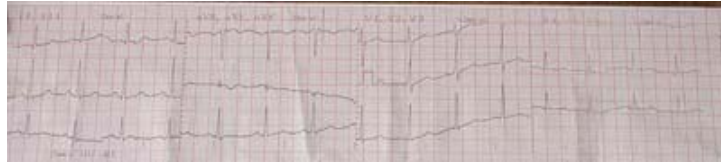Limb: unremarkable

Previous Labs/Studies: result of blood work done at SHCH on 08/04/04

THS: 0.75micro IU/ml
T4: 11 pml/L
Na+: 135mmol/L
Creat: 66umol/L
Glucose: 44mmol/L
WBC: 7
RBC: 4.9
Hgb: 10.3
HCT: 30
MCV: 61
MCH: 21
MCHC: 34
Platelets count: 294



Lab/Study Requests: none



Assessment:

16. Tension head ache
17. Dyspepsia
18. Vit deficiency
19. Bening neck cyst?

Plan: we would cover her with some medication as the following

23. Paracetamol 500mg 1 tab PO 4 times per day for PRN
24. Tums 1g 1tab PO 2 times per day for 2 months
25. Multivitamine 1 tab PO 1 time per day for 2 months

Comments: if you have any comment or idea please give me

Examined by: Koy Somontha, RN **Date:** 12/05/04

Please send all replies to tmrural@yahoo.com and cc: to tmed_rithy@online.com.kh and tmed_project@online.com.kh. If unable to send to the first address, please send replies to tmed_ruralcam@yahoo.com as an alternative address.

The information transmitted in this e-mail is intended only for the person or entity to which it is addressed and may contain confidential and/or privileged material. Any review, retransmission, dissemination or other use of or taking of any action in reliance upon, this information by persons or entities other than the intended recipient is prohibited. If you received this e-mail in error, please contact the sender and delete material from any computer.

-----Original Message-----

From: Kelleher-Fiamma, Kathleen M. - Telemedicine
[mailto:KKELLEHERFIAMMA@PARTNERS.ORG]
Sent: Thursday, May 13, 2004 4:50 AM

To: 'tmrural@yahoo.com'
Cc: 'tmed_rithy@online.com.kh'; 'tmed_project@online.com.kh';
'tmed_rithy@bigpond.com.kh'
Subject: RE: Robib TM Clinic May 04, Patient 08, Em Kheav, 43F

-----Original Message-----

From: Kelleher-Fiamma, Kathleen M. - Telemedicine
Sent: Wednesday, May 12, 2004 8:47 AM
To: Smulders-Meyer, Olga,M.D.
Subject: FW: Robib TM Clinic May 04, Patient 08, Em Kheav, 43F

Hi Olga:

Here is a follow-up case for you. If you need the previously presented material, please let me know.

Kathy

-----Original Message-----

From: Smulders-Meyer, Olga,M.D.
To: Kelleher-Fiamma, Kathleen M. - Telemedicine
Sent: 5/12/04 4:48 PM
Subject: RE: Robib TM Clinic May 04, Patient 08, Em Kheav, 43F

EM Kheav, 43 F from Thnal Village.

the patient has a TSH of 0.75, which is still in normal limits, so she is not hyperthyroid yet. She still has a mid neck mass, and we do recommend that she gets a fine needle biopsy to assure it is a benign lesion. The lesion is very easy to reach and this biopsy can be done with a fine needle.. You need to be sure that she does not have a malignancy in her neck.

She is anemic> she is a premenstrual female, presumable with regular menstrual periods , and most likely she is iron deficient. Her MCV is low, which is consistent with with iron deficient anemia. The patient is tachycardic and this might be related to her anemia. In this light we recommend starting her on iron supplements twice a day for 2-3 months and then recheck her CBC to ensure that it is improving.

She has a history of chronic tension headaches . I would not advise the patient to take pain meds, like paracetamol, on a daily basis as she might develop withdrawal headaches if she stops the medications. Instead, you could consider a low dose Atenolol 25 mg at first, and if she tolerates it, increase it to 50 mg, to be taken every night, to see if this prevents the headaches from occurring. For acute headaches , she can take 2 paracetamols. Her heartrate will be able to tolerate a B Blocker without difficulty, and it fact it might improve her palpitations .

her EKG is hard to interpret as there are few leads, but she is sinus rhythm, slightly tachycardic.

The patient complains of pain in epigastric area. You could treat her with antiacids for about a month, but if her symptoms persist, you could try Zantac for 6 weeks, but after that I would advice you to get an Upper Gi or an endoscopy, to rule out gastric cancer, or a gastric ulcer.

She complains of blurred vision and she needs to be examined by an eyedoctor. Maybe she may need glasses.

I cannot find any causes for excessive salivation except salivary gland tumors. i would re examine her again very carefully in her oral cavityi and ensure that there are no masses there. If none found, I would advise the patient to increase her intake of plain water for a while and see if this clears it up

Olga Smulders-Meyer, MD -

-----Original Message-----

From: Jennifer Hines [mailto:jghines@hotmail.com]

Sent: Thursday, May 13, 2004 9:47 AM

To: tmrural@yahoo.com; tmed_rithy@online.com.kh;

tmed_project@online.com.kh

Subject: Telemedicine replies for cases #6-11 Robib Clinic, 13 May 2004

Dear Montha:

Case #8 Em Kheav, 43F

I wanted to understand how you are assessing this woman's eye complaints. She has blurred vision. What does that mean? Could she be having blurred vision and headache because she needs glasses? Can she read? Does she have double vision or black spots in her vision, etc. Can she get her eye checked anywhere?

This woman appears to have dyspepsia. Did we consider H. pylori eradication in her? This infection is so endemic (common) to Cambodia that we should consider it and treat. Again, it is omeprazole 40mg BID + Amoxicillin 1 g BID + Clarithromycin 500mg BID for 10 days. We will have to prepackage this in your supplies for the next visit. Using TUMS for now is fine.

What vitamin deficiency does she have? She has a mild anemia, but I do not know if it is related to a lack of vitamins. What is her diet like? Does she eat fruit, vegetables, meat? If so, I don't think MVI is needed in this patient.

Thanks, Jennifer

-----Original Message-----

From: TM Team [mailto:tmrural@yahoo.com]

Sent: Wednesday, May 12, 2004 6:09 PM

To: Rithy Chau; Jennifer Hines; Bunse Leang; Heather Brandling Bennett; Paul Heinzelmann; Kathy Kelleher-Fiamma; Joseph Kvedar

Cc: Somontha Koy; Bernie Krisher; Nancy Lugn; SoThero Noun

Subject: Robib TM Clinic May 04, Patient 09, Ke Ourn, 48F

Dear all,

This is the ninth case and photos.

Regards,

Montha

Please send all replies to tmrural@yahoo.com and cc: to tmed_rithy@online.com.kh and tmed_project@online.com.kh.

The information transmitted in this e-mail is intended only for the person or entity to which it

is addressed and may contain confidential and/or privileged material. Any review, retransmission, dissemination or other use of or taking of any action in reliance upon, this information by persons or entities other than the intended recipient is prohibited. If you received this e-mail in error, please contact the sender and delete material from any computer.

Robib Telemedicine Clinic
Sihanouk Hospital Center of HOPE and Partners in Telemedicine
Rovieng Commune, Preah Vihear Province, Cambodia



Patient: Ke Ourn, 48F from Thnoal Keng village

Subject: 48F, returned for her follow up of Bell's palsy, Vit deficiency ? She still has head ache, neck tender, palpitation, but no fever, no SOB, no cough, No GI complain. Last strip, we also order her go to Kg Thom to do CXR , EkG, and HIV test (she support by her own)

Object:

VS: BP110/50 P 90 R20 T 36.5 Wt 34kgs

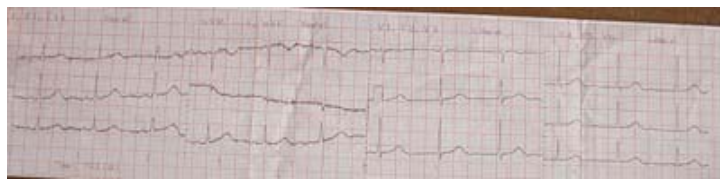
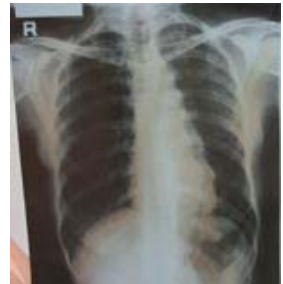For PE look the same of last month note, please look at it

Previous Labs/Studies: EKG and CXR we will attach through pictures and result of HIV is Negative

Lab/Study Requests: none

Assessment:

20. Bell's Palsy
21. Vit Difeciency?
22. Tension Head ache



Plan: we would cover her with some medications for 2 months of

26. Mlitivitamine 1tab PO 1 time per day with food
27. Becomplex 1tab Po 1 time per day
28. Paracetamol 500mg 1tab PO 4 times per day for PRN
29. Recoment patient still use left eye patch at night time

Comments: if you any idea or comment please give me

Examined by: Koy Somontha, RN **Date:** 12/05/04

Please send all replies to tmrural@yahoo.com and cc: to tmed_rithy@online.com.kh and tmed_project@online.com.kh. If unable to send to the first address, please send replies to tmed_ruralcam@yahoo.com as an alternative address.

The information transmitted in this e-mail is intended only for the person or entity to which it

is addressed and may contain confidential and/or privileged material. Any review, retransmission, dissemination or other use of or taking of any action in reliance upon, this information by persons or entities other than the intended recipient is prohibited. If you received this e-mail in error, please contact the sender and delete material from any computer.

-----Original Message-----

From: Paul [mailto:ph2065@yahoo.com]

Sent: Thursday, May 13, 2004 5:57 AM

To: tmrural@yahoo.com; tmed_rithy@online.com.kh; tmed_project@online.com.kh

Cc: kkelleherfiamma@partners.org; kkelleher-fiamma@partners.org

Subject: Patient: Ke Ourn, 48F from Thnoal Keng village

Patient: Ke Ourn, 48F from Thnoal Keng village

Thank you for the update.

Her EKG, and CXR appear normal.

As I mentioned in my reply in April, she likely had a case of cerebral malaria and the facial droop is a result of that. I don't believe that the facial droop can be corrected. The eye patch at night should be continued if it is helping.

More information about her headache would be helpful (Where, quality, duration, visual changes, etc.) I would look for simple causes first such as mild dehydration by checking orthostatic vital signs.

Because of her tender neck and palpitations, a TSH/T4 would be helpful to rule out hyperthyroidism. I know this is difficult to obtain however.

B vitamins, multi-vitamin and paracetamol can be continued.

I hope this was helpful.

Paul Heinzelmann, MD

-----Original Message-----

From: Jennifer Hines [mailto:jghines@hotmail.com]

Sent: Thursday, May 13, 2004 9:47 AM

To: tmrural@yahoo.com; tmed_rithy@online.com.kh;

tmed_project@online.com.kh

Subject: Telemedicine replies for cases #6-11 Robib Clinic, 13 May 2004

Dear Montha:

Case #9 Ke Ourn, 48F

It is not convenient always to check back and see an PE from a previous visit. Each visit should have its own assessment. If this lady has been coming to the clinic for months and there is no change in her condition, which does happen with Bell's palsy, then she should be dismissed from the clinic. None of the medication that you are giving her will really help this condition. I recommend stopping everything and discharging her from the clinic. She

knows how to care for her face and protect her eye from trauma at night.

As you know, Bell's palsy has an unknown cause and in this environment, could be associated with early HIV infection. Did she get her test back? What is the result? If she is HIV+, the testing center should be able to help refer her somewhere for follow-up. This is not the function of the

Telemedicine Clinic.

Thanks, Jennifer

-----Original Message-----

From: TM Team [mailto:tmrural@yahoo.com]

Sent: Wednesday, May 12, 2004 8:10 PM

To: Rithy Chau; Jennifer Hines; Bunse Leang; Paul Heinzelmann; Kathy Kelleher-Fiamma; Joseph Kvedar; Heather Brandling Bennett

Cc: Somontha Koy; Bernie Krisher; Nancy Lugn; SoThero Noun

Subject: Robib TM clinic May 04, Patient 10, Tho Chanthy, 37F

Dear all,

This is the tenth case and photo.

Regards,

Montha

Please send all replies to tmrural@yahoo.com and cc: to tmed_rithy@online.com.kh and tmed_project@online.com.kh.

The information transmitted in this e-mail is intended only for the person or entity to which it is addressed and may contain confidential and/or privileged material. Any review, retransmission, dissemination or other use of or taking of any action in reliance upon, this information by persons or entities other than the intended recipient is prohibited. If you received this e-mail in error, please contact the sender and delete material from any computer.

**Robib Telemedicine Clinic
Sihanouk Hospital Center of HOPE and Partners in Telemedicine
Rovieng Commune, Preah Vihear Province, Cambodia**



Patient: Tho Chanthy, 37F from Thnout Malou village

Subject: 37F return for her follow up of Hyperthyoidism. She feels much improving with her previous symptoms, still has slight bilateral eye pressure, mild head ache, mild neck tender, mild blurred vision. But no fever, no cough, no GI complain.

Object:

VS: BP 120/70 P 68 R 20 T36.5 Wt didn't check

For her physical exam is the same from last month note, please

look at it.

Previous Labs/Studies: look at in last month note

Lab/Study Requests:

Assessment:

23. Hyperthyroidism
24. Tension Head ache

Plan: we would like to go on with the same of medications and cover for another month

30. Carbimazole 5mg 1tab PO 1 time per day
31. Propranolol 40mg ¼ tab PO 2 time per day
32. ASA 300mg ¼ tab PO 1 time per day
33. Paracetamol 500mg 1tab PO 4 times per day
34. We want to recheck her Thyroide function test and CBC , which will be done at SHCH.

Comments: do you agree? If you any comment or idea please give me

Examined by: Koy Somontha, RN **Date:** 12/05/04

Please send all replies to tmrural@yahoo.com and cc: to tmed_rithy@online.com.kh and tmed_project@online.com.kh. If unable to send to the first address, please send replies to tmed_ruralcam@yahoo.com as an alternative address.

The information transmitted in this e-mail is intended only for the person or entity to which it is addressed and may contain confidential and/or privileged material. Any review, retransmission, dissemination or other use of or taking of any action in reliance upon, this information by persons or entities other than the intended recipient is prohibited. If you received this e-mail in error, please contact the sender and delete material from any computer.

-----Original Message-----

From: Kelleher-Fiamma, Kathleen M. - Telemedicine
Sent: Wednesday, May 12, 2004 9:51 AM
To: Crocker, Jonathan T., M.D.
Subject: FW: Robib TM clinic May 04, Patient 10, Tho Chanthy, 37F

Hello Dr. Crocker:

Here is another follow up case for you. If you need the previously presented material, please let me know.

Regards,

Kathy

-----Original Message-----

From: Kelleher-Fiamma, Kathleen M. - Telemedicine
[mailto:KKELLEHERFIAMMA@PARTNERS.ORG]
Sent: Thursday, May 13, 2004 2:21 AM
To: 'tmrural@yahoo.com'
Cc: 'tmed_rithy@online.com.kh'; 'tmed_project@online.com.kh'
Subject: FW: Robib TM clinic May 04, Patient 10, Tho Chanthy, 37F

Hi Koy,

I fully agree with your assessment and plan for her. Monitor her thyroid function tests as you have planned. You might want to check out her visual acuity to see if that's a cause (e.g myopia) for her headaches.

Best,

Jon Crocker, MD

-----Original Message-----

From: Jennifer Hines [mailto:jghines@hotmail.com]

Sent: Thursday, May 13, 2004 9:47 AM

To: tmrural@yahoo.com; tmed_rithy@online.com.kh;

tmed_project@online.com.kh

Subject: Telemedicine replies for cases #6-11 Robib Clinic, 13 May 2004

Dear Montha:

Case #10 Tho Chanthy, 37F

It is helpful to say in your note, how long your patient has been on therapy. I am not sure she needs to continue Propranolol and Carbimazole at such low doses. I agree to continue the medications as prescribed and to repeat T4 and TSH at SHCH. Again, it is really good to reassess your patient and document the exam instead of saying, "the same as last visit," You see these patients once a month, so things can change in between visits.

Thanks, Jennifer

-----Original Message-----

From: TM Team [mailto:tmrural@yahoo.com]

Sent: Wednesday, May 12, 2004 8:25 PM

To: Rithy Chau; Jennifer Hines; Bunse Leang; Paul Heinzelmann; Kathy Kelleher-Fiamma; Joseph Kvedar; Heather Brandling Bennett

Cc: Somontha Koy; Bernie Krisher; Nancy Lugn; SoThero Noun

Subject: Robib TM clinic May 04, Patient 11, Muy Vun, 38M

Dear all,

This is the last case and photos.

Regards,

Montha

Please send all replies to tmrural@yahoo.com and cc: to tmed_rithy@online.com.kh and tmed_project@online.com.kh.

The information transmitted in this e-mail is intended only for the person or entity to which it is addressed and may contain confidential and/or privileged material. Any review, retransmission, dissemination or other use of or taking of any action in reliance upon, this information by persons or entities other than the intended recipient is prohibited. If you received this e-mail in error, please contact the sender and delete material from any

computer.

Robib Telemedicine Clinic
Sihanouk Hospital Center of HOPE and Partners in Telemedicine
Rovieng Commune, Preah Vihear Province, Cambodia



Patient: Muy Vun, 38M from Thnout Malou village

Subject: 38M, return for his follow up of his Afib with Valvulo heart disease, and Gastritis. He feels much better by decreasing SOB, decrease palpitation, decrease epigastric pain head ache, but no fever, no cough, no chest pain, no peripheral edema, no GI complain

Object:

VS: BP 100/60 P 80 R 20 T 36.5 Wt 61kgs

HEENT : unremarkable

Neck : no JVD, no thyroide glance seen, no lymphnode palpable

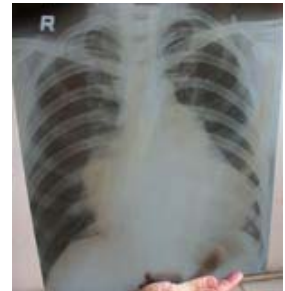
Skin: warm to touch, no cynosis, not pale

Lungs: clear both sides

Heart: RRR, no murmur

Abdomen: soft, flat, no tender, no HSM,
positive bowel sound

Limbs: no pitting edema

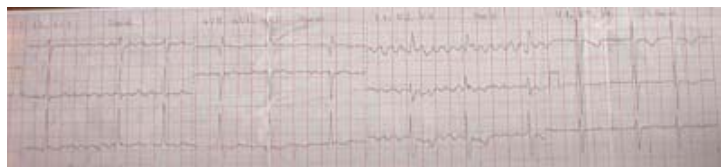

1

Previous Labs/Studies: on 30/04/04 he did CXR and EKG at Kg Thom Hospital

CXR shows cardiomegaly

EkG shows Aterial Flutter with PR:0.22sec, QRS: 0.08secon, P to P irregular, many P before QRS complex, HR around 72 beat/mn



Lab/Study Requests: none

Assessment:

25. Aterial Flutter with Valvulo heart desease
26. Gastritis

Plan: we would like to cover her with some medications for another month as the follow wing

35. Digoxine 0.25mg 1 tab PO 1 time per day
36. ASA 300mg ¼ tab PO 1 time per day
37. Ranitidine 75mg 2tab PO 2 times per day
38. We want to draw his blood for Lyte, Creat, BUN, and CBC which will be done at SHCH

Comments: do you agree? If you have any comment or idea, please give me

Examined by: Koy Somontha, RN **Date:** 12/05/04

Please send all replies to tmrural@yahoo.com and cc: to tmed_rithy@online.com.kh and tmed_project@online.com.kh. If unable to send to the first address, please send replies to tmed_ruralcam@yahoo.com as an alternative address.

The information transmitted in this e-mail is intended only for the person or entity to which it is addressed and may contain confidential and/or privileged material. Any review, retransmission, dissemination or other use of or taking of any action in reliance upon, this information by persons or entities other than the intended recipient is prohibited. If you received this e-mail in error, please contact the sender and delete material from any computer.

-----Original Message-----

From: Kelleher-Fiamma, Kathleen M. - Telemedicine
[mailto:KKELLEHERFIAMMA@PARTNERS.ORG]
Sent: Thursday, May 13, 2004 4:44 AM
To: 'tmrural@yahoo.com'
Cc: 'tmed_rithy@online.com.kh'; 'tmed_project@online.com.kh';
'tmed_rithy@bigpond.com.kh'
Subject: FW: Robib TM clinic May 04, Patient 11, Mui Vun, 38M

-----Original Message-----

From: Kelleher-Fiamma, Kathleen M. - Telemedicine
Sent: Wednesday, May 12, 2004 9:48 AM
To: Sadeh, Jonathan S.,M.D.
Subject: FW: Robib TM clinic May 04, Patient 11, Mui Vun, 38M

Hello Dr. Sadeh:

Attached, please find a follow-up case for a patient that you have been following. If you would like the previously presented material and your response, please let me know.

Best,

Kathy

-----Original Message-----

From: Sadeh, Jonathan S.,M.D.
To: Kelleher-Fiamma, Kathleen M. - Telemedicine
Sent: 5/12/04 5:22 PM
Subject: RE: Robib TM clinic May 04, Patient 11, Mui Vun, 38M

Sounds like he's doing better than before. He's not in heart failure clinically or by CXR and is well rate controlled. I would agree with continuing digoxin for rate control and a full aspirin (325 mg) for anti coagulation--he is at very high risk for embolic disease with his MS and atrial flutter. Checking labs would be good and again trying to convince him to go for an evaluation at a hospital for repair of his valve.
Jonathan Sadeh.

-----Original Message-----

From: Jennifer Hines [mailto:jghines@hotmail.com]

Sent: Thursday, May 13, 2004 9:47 AM

To: tmrural@yahoo.com; tmed_rithy@online.com.kh;

tmed_project@online.com.kh

Subject: Telemedicine replies for cases #6-11 Robib Clinic, 13 May 2004

Dear Montha:

Case #11 Muy Vun, 38M

I think I would decrease this man's digoxin to 0.125mg QD and continue the ASA. Atrial flutter can be an unstable rhythm and in your exam, you state that his rhythm is regular. Is he in sinus rhythm now? Please remember to tell this man that alcohol can make his heart rhythm worse. Has he had thyroid tests to make sure thyroid disease is not causing this condition?

Anyway, I agree with the other medications, although, again, did this patient ever have H. pylori eradication? Please consider for next visit.

Great job, Montha.

Thanks, Jennifer

Thursday, May 13, 2004

Follow-up Report for Robib TM Clinic

There were 11 patients seen during this month Robib TM Clinic. The data of all cases were transmitted and received replies from both Phnom Penh and Boston. Per advice sent by Partners in Boston and Phnom Penh Sihanouk Hospital Center of HOPE, the following patients were managed and treated as follows:

[Please note that some blood works was drawn and done at SHCH at no cost and others including studies such as x-rays, U/S, EKG, etc. were done at Kompong Thom Referral Hospital with patients paying own their own. Robib TM clinic no longer pays for transportation, accommodation, and other expenses for the patients visiting the clinic whether they are from Thnout Malou Village or not. For those patients who were seen at SHCH previously and remained stable with medications, the clinic would continue to provide them with appropriate medications from SHCH at no cost for the duration of their illnesses or while supplies lasted. The clinic still provided free medications for all "poor" patients, especially if they are from Thnout Malou Village. Also, 6 patients came by for refills of medications and they were listed below.]

-

1-Tan Kim Horn, 55F, Thnout Malou village

Diagnosis:

1- DMII?

Treatment and plan:

- 1- Draw blood for blood work like (BUN, Creat, Lyte, Glycemia, CBC), these will be done at SHCH.
- 2- EKG, CXR, Transamina, Urine Microscopic at Kg Thom by herself.
- 3- Diabetes Education.

2- Phnom Sok Chea, 9M, Thnal Keng village

Diagnosis:

- 1- Pneumonia
- 2- Mulnutrition
- 3- Parasitis?

Treatment and plan:

- 1- Erythromicine 250mg 1tab po q6h for 7 days #28tab
- 2- Paracetamol 500mg 1/2tab po q6h for PRN # 14tab
- 3- Multivitamin 1 tab po qd for 1 month # 30tabs
- 4- Mebandazole 100mg 1tab po qbid for 3 days # 6 tabs

3- Cheng Rady, 9F, Thnou Malou village

Diagnosis:

- 1- Pneumonia?
- 2- Parasitis?

Treatment and plan:

- 1- Erythromycine 250mg 1tab po q6h for 7 days # 28tab
- 2- Mebandazole 100mg 1tab po qbid for 3 days # 6 tab
- 3- Paracetamol 500mg 1/2tab po q6h for PRN # 14tab

4- Lay Neung, 35F, Sleing Toul village

Diagnosis:

- 1- Euthyroide?
- 2- Tension Headache
- 3- Dyspepsia?
- 4- Parasitis?

Treatment and plan:

- 1- Propranolol 40mg 1/4tab po qd for 2 months # 15tab

- 2- Tump 1g 1tab po qbid for 2 months # 120tab
- 3- Mebendazole 100mg 1tab po bid for 3 days # 6tab
- 4- Paracetamol 500mg 1 tab po q6h for PRN # 40tab

5- Thorng Khun, 39F, Thnout Malou vilage

Diagnosis:

- 1- Euthyroide with breast-feeding 5 months child.
- 2- Tension headache

Treatment and plan:

- 1- Multivitamine 1tab po qd for 2 months # 60tab
- 2- Draw blood to recheck he Thyroide function test, it will be done at SHCH

6- Som Doeum, 65F, Thnout Malou vilage

Diagnosis:

- 1- Poly Arthritis

Treatment and plan:

- 1- Nabumetone 750mg 1tab po qbid for 2 months # 120tab
- 2- Chloroquine 250mg 1tab po qd for 2 months # 60tab

7- Chan Sokny, 25F, Thnout Malou vilage

Diagnosis:

- 1-Euthyroide
- 2- Tension Headache

Treatment and plan:

- 1- Propranolol 40mg 1/4 tab po qbid for 2 months # 30tab
- 2- Fer/ folic 200/0.25mg 1tab po qd for 2 months # 60tab
- 3- Paracetamol 500mg 1tab po q6h PRN # 40tab_

8- Em Kheav, 43F, Thnal Keng vilage

Diagnosis:

- 1- Tension Headache
- 2- Dyspepsia
- 3- Vit Deficiency?

4- Bening Neck Cyst?

Treatment and plan:

- 1- Tump 1g 1tab po qbid for 2 months # 86tab
- 2- Paracetamol 500mg 1tab po q6h PRN # 40tab
- 3- Multivitamine 1tab po qd for 35days # 35tab

9- Ke Ourn, 48F, Thnal Keng village

Diagnosis:

- 1- Bell's Palsy
- 2- Tension Headache
- 3- Vit Deficiency?

Treatment and plan:

- 1- Paracetamol 500mg 1tab po q6h PRN # 30tab
- 2- Multivitamine 1tab po qd for 2 months # 60tab

10- Tho Chanthy, 37F, Thnout Malou village

Diagnosis:

- 1- Hyperthyroidism
- 2- Tension Headache

Treatment and Plan:

- 1- Carbimazole 5mg 1tab po qd for 1 month # 30tab
- 2- Propranolol 40mg 1/4tab po qbid for 1month # 15tab

11- Mui Vun, 38M, Thnout Malou village

Diagnosis:

- 1- Aterial Flutter
- 2- Valvulo Heart Disease (MR? MS?)
- 3- Gastritis

Treatment and plan:

- 1- Digoxine 0.25mg 1tab po qd for 1month # 30tab
- 2- ASA 500mg 1/4tab po qd for 1 month # 8tab
- 3- Ranitidine 75mg 2tab po qbid for 1 month # 120tab
- 4- Draw blood for Lyte, BUN, Creat, CBC, BS. These tests will be

done at SHCH

Data were not transmitted for the following patients (because they came only for refills of medications):

1-Pen Vanna, 38F, Thnout Malou village

Diagnosis:

1- HTN

2- Gastritis

Treatment and Plan:

1- HCTZ 50mg 1/2tab po qbid for 1month # 30tab

2- ASA 500mg 1/4tab po qd for 1 month # 8tab

3- Omeprazole 20mg 1tab po qhs for 1 month # 30tab

3-Pheng Roeun, 56F, Thnout Malou village

Diagnosis:

1- Hyperthyroidism

Treatment and plan:

1- Propranolol 40mg 1/4tab po qbid for 1 month # 15tab

2- Carbimazole 5mg 1tab po qbid for 1 month # 60tab

3- Multivitamine 1tab po qd for 1 month # 30tab

4-Som Thol, 51M, Tang Treuk village

Diagnosis:

1- DMII with PNP

Treatment and plan:

1- Diamecron 80mg 1.5tab po qd for 1 month # 45tab

2- Captopril 25mg 1/4tab po qd for 1 month # 8tab

3- Amitriptilline 25mg 1tab po qbid for 1 month # 60tab

4- ASA 500mg 1/4tab po qd for 1 month # 8tab

5-Soa Phal, 57F, Thnout Malou

Diagnosis:

1- DMII with PNP

Treatment and plan:

- 1- Diamecron 80mg 1/2tab po qd for 1 month # 15tab
- 2- HCTZ 50mg 1/2tab po qd for 1 month # 15tab
- 3- Captopril 25mg 1/4tab po qd for 1 month # 8tab
- 4- Amitriptilline 25mg 1tab po qd for 1 month # 30tab
- 5- ASA 500mg 1/4tab po qd for 1 month # 8tab

6-Nget Soeun, 57M, Thnout Malou

Diagnosis:

- 1- Liver Cirrhosis

Treatment and plan:

- 1- Aldactone 50mg 1/2tab po qd for 1 month # 30tab
- 2- Propranolo 1/2tab po qd for 1 month # 15tab
- 3- Multivitamine 1tab po qd for 1 month # 30tab

The next Robib TM Clinic will be held on June 8-10, 2004